

Gastroesophageal reflux as a predictor of complications after adenotonsillectomy in young children[☆]

Michael E. McCormick^{a,*}, Anthony Sheyn^b, Michael Hauptert^c, Adam J. Folbe^{b,c}

^a Department of Otolaryngology and Communication Sciences, Division of Pediatric Otolaryngology, Medical College of Wisconsin, Milwaukee, WI, United States

^b Department of Otolaryngology – Head & Neck Surgery, Wayne State University School of Medicine, Detroit, MI, United States

^c Department of Otolaryngology, Children's Hospital of Michigan, Detroit, MI, United States

ARTICLE INFO

Article history:

Received 14 June 2013

Received in revised form 9 July 2013

Accepted 16 July 2013

Available online 9 August 2013

Keywords:

Tonsillectomy

Adenoidectomy

Complications

Airway obstruction

Young children

Gastroesophageal reflux

ABSTRACT

Objective: To examine characteristics of young children with gastroesophageal reflux (GER) who experienced complications within the first 24 h after adenotonsillectomy.

Study design: Subset analysis of a larger retrospective cohort.

Methods: A retrospective chart review was performed at a tertiary care children's hospital. Consecutive records of children 3 years old and younger undergoing adenotonsillectomy (AT) over a 5-year period were reviewed. Children with a clinical history of GER were selected for the study.

Results: 993 children were included in the initial analysis, and GER was found to be a significant independent variable predictive of early complications. 81 children with a history of GER were included in this study and 8 (9.9%) were found to have experienced complications within the first 24 h. Six of the complications were airway-related; two required re-intubation within the first 24 h. All 8 children with complications had symptoms of sleep-disordered breathing and two had documented severe obstructive sleep apnea (AHI 18.6 and 27.2). Seven children had other risk factors for complications after AT. Eighteen (22%) children had a prolonged length of stay (range 2–7 days); additional risk factors were present in these patients as well.

Conclusions: Knowledge of risk factors for complications following adenotonsillectomy is critical for identifying at-risk patients that may warrant closer post-operative observation. GER has been previously identified as a risk factor for complications in young children. Upon closer analysis, young children with GER who have other known risk factors may be at a further increased risk for airway complications and prolonged hospitalization. Parents of these children can be counseled on the post-operative risks and the possibility of a longer hospitalization.

© 2013 Published by Elsevier Ireland Ltd.

1. Introduction

Tonsillectomy with or without adenoidectomy (AT) is one of the most common outpatient procedures performed in the United States [1,2]. The overall complication rate (early and late) for AT is estimated to be between 2 and 10% [3]; early post-operative complications include pain, hemorrhage, nausea, vomiting, dehydration, and post-obstructive pulmonary edema. Known risk factors for complications after AT include obstructive sleep apnea syndrome, craniofacial abnormalities, Down's syndrome, cerebral

palsy, obesity, bleeding disorders, and age younger than 3 years old [1,4–10].

In a recent retrospective review of 993 patients age 3 or younger who had undergone AT, we identified a number of independent variables predictive of early complications using multivariate analysis [11]. Consistent with previously published studies were the identification of prematurity and cardiovascular anomalies as predictors of early complications and also the identification of younger age (less than 3) as a predictor of airway complications. A unique and novel finding of this study was the identification of gastroesophageal reflux as an independent predictor of early complications.

Gastroesophageal reflux (GER) has gained increased interest in the pediatric otolaryngology community over the last two decades [12–15]. With the increasing role of GER in otolaryngologic diseases, as well as our recent association of GER with early post-operative complications after AT, we further analyzed the subset of

[☆] Poster presentation at American Society of Pediatric Otolaryngology, San Diego, CA, April 2012.

* Corresponding author at: Division of Pediatric Otolaryngology, Children's Hospital of Wisconsin, 9000 W. Wisconsin Avenue, Suite 540, Milwaukee, WI 53226, United States. Tel.: +1 414 266 6393; fax: +1 414 266 2693.

E-mail address: mmccormick@mcw.edu (M.E. McCormick).

children 3 years old and younger with GER who underwent adenotonsillectomy.

2. Methods

We initially performed a retrospective chart review with Institutional Review Board approval of all children 3 years old and younger undergoing adenotonsillectomy at the Children's Hospital of Michigan between July 1, 2005 and June 30, 2010. Charts were reviewed for demographic data, pre-operative symptoms and conditions, and postoperative hospitalization details, including time to adequate oral (PO) intake, complications, and length of stay (LOS). Comorbid conditions, including gastroesophageal reflux, were included when identified during historical chart review of our institution's records alone. Objective diagnostic testing for GER was not always present in our institution's records, and therefore was not included in the analysis.

Primary outcomes for the initial evaluation included: total complications on post-operative days (POD) 0–1, airway complications on POD 0–1, and length of stay (LOS). Our initial analysis using multivariate logistic regression models has previously been published [11]. Gastroesophageal reflux was identified as an independent predictor of both overall complications and prolonged length of stay (≥ 2 days). A subset analysis was performed and closely examined all children in the cohort with a history of GER in an effort to further characterize these children and their post-operative course.

3. Results

Initially, 993 children were included in the primary analysis and their characteristics have been previously published [11]. Of this original cohort, eighty-one were found to have had a history of gastroesophageal reflux. Of those 81 children, 8 (9.9%) experienced complications within the first 24 h post-operatively. Their characteristics can be seen in Tables 1 and 2. Almost all of the

children in both groups had symptoms of sleep-disordered breathing (100% of children with complications, 93.2% of children without complications). Children with GER who experienced complications were younger (median age 26.0 months vs. 31.5 months) and had more associated co-morbid conditions (Fig. 1). Additionally, more severe obstructive sleep apnea (OSA) was seen in children with complications (median AHI 22.9 vs. 12.1).

The average length of stay (LOS) of the 81 children with GER was 1.09 days; children without GER went home after 0.84 days. Eighteen (22.2%) children with GER required hospitalizations longer than the expected 24 h. Longer LOS (≥ 2 days) was seen more often in younger children (median age 26.1 months vs. 32.3 months) and children with cardiovascular anomalies, abnormal airways, or craniofacial syndromes (Fig. 2). In addition, children with more severe OSA on pre-operative polysomnography experienced longer hospitalizations (median AHI 21.2 vs. 8.4).

Post-operative complications in children with gastroesophageal reflux occurred in the presence of other known risk factors in all 8 children. Two patient examples are provided:

Patient #4 was a 23-month old male with a history of prematurity, Beckwith–Wiedemann syndrome, and gastroesophageal reflux. He had previously undergone an adenoidectomy and glossectomy but he continued to have heroic snoring, gasping, and witnessed apneas. Polysomnography demonstrated an apnea–hypopnea index of 27.2. He underwent tonsillectomy with concurrent direct laryngoscopy, bronchoscopy, and esophagoscopy. He developed respiratory distress and inspiratory stridor and was transferred to the pediatric intensive care unit (PICU) for monitoring. He did well overnight and was transferred to the surgical floor where he was discharged on post-operative day #2.

Patient #6 was an 18-month old male who presented with symptoms of snoring and witnessed apneas. He also had chronic otitis media with effusion, reflux, and a history of aortic stenosis. He underwent adenotonsillectomy and bilateral

Table 1
Demographic and pre-operative characteristics of patients who experienced complications.

Patient #	Age (months)	Gender	SDB	Asthma	Prematurity	Cardiovascular anomalies	Seizures	Airway findings	PSG (AHI)
1	14	F	Y	Y	N	N	N	N	N
2	43	M	Y	N	N	N	N	N	N
3	35	F	Y	N	N	N	Y	Y ^c	Y (18.6)
4	23	M	Y	N	Y	Y ^a	N	Y ^d	Y (27.2)
5	27	M	Y	N	Y	N	N	N	N
6	18	M	Y	N	N	Y ^b	N	N	N
7	36	M	Y	Y	Y	N	N	N	N
8	25	F	Y	N	N	N	N	N	N
TOTAL	27.6	5M/3F	100%	25%	37.5%	25%	12.5%	25%	25%

^a Atrial septal defect.

^b Aortic stenosis.

^c Laryngeal cleft.

^d Beckwith–Wiedemann syndrome.

Table 2
Operative and post-operative details of patients who experienced complications.

Patient #	Primary procedure	Other procedures	Admit location	LOS	Details
1	AT	Y ^a	PICU	1	Desaturations requiring High-Flow Nasal Cannula
2	AT	Y ^a	FLOOR	2	Desaturations requiring non-rebreather mask, transferred to PICU
3	AT	Y ^a	PICU	2	Post-obstructive pulmonary edema
4	T	Y ^a	PICU	2	Desaturations and stridor in recovery unit, admitted to PICU for monitoring
5	AT	N	PICU	2	Desaturations and CO ₂ retention requiring re-intubation
6	AT	Y ^b	PICU	2	Desaturations and stridor in recovery unit requiring re-intubation
7	AT	N	HOME	0	Returned to hospital for dehydration on POD#1
8	AT	Y ^a	FLOOR	2	Primary post-tonsillectomy bleed in recovery unit requiring re-operation

^a Direct laryngoscopy, bronchoscopy, esophagoscopy.

^b Bilateral myringotomy and tympanostomy tube insertion.

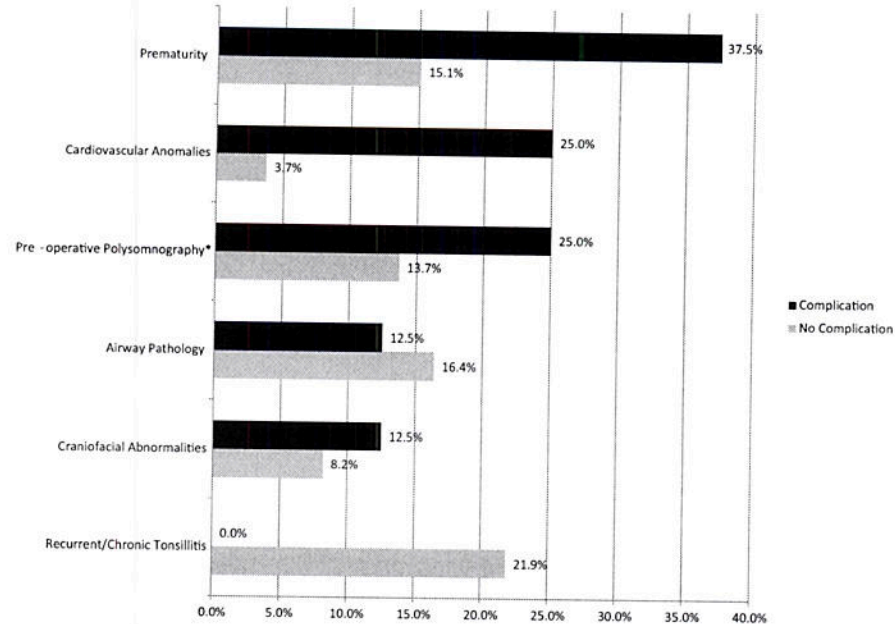


Fig. 1. Complications. Patients with GER who experienced complications had a higher percentage of prematurity and co-existing cardiovascular anomalies. When pre-operative PSG (*) was performed, these patients showed more severe OSA as well (median AHI 22.9 vs. 8.8).

myringotomy with tympanostomy tube insertion. In the recovery unit, he was noted to have stridor and retractions and a blood gas revealed hypoxemia and acidosis. He was intubated and transferred to the PICU. He self-extubated during his first post-operative night but remained stable and was discharged home on post-operative day #1.

4. Discussion

The AAO-HNS has published guidelines regarding many key issues regarding tonsillectomy in children, including indications for the procedure and antibiotic use in the perioperative period [1].

The currently known risk factors for post-operative complications following adenotonsillectomy include: bleeding disorders, severe obstructive sleep apnea, craniofacial syndromes, major cardiac disease, and age less than 3 years old [1,3–5,8–10,16]. We recently identified gastroesophageal reflux (GER) as an independent risk factor for early complications in children 3 years old and younger [11]. GER was also significantly associated with an increased length of stay (≥ 2 days) in these children ($p = 0.017$). With the identification of this novel risk factor, we performed a closer analysis of the 81 children in our cohort with GER in order to better understand how GER contributed to their postoperative course.

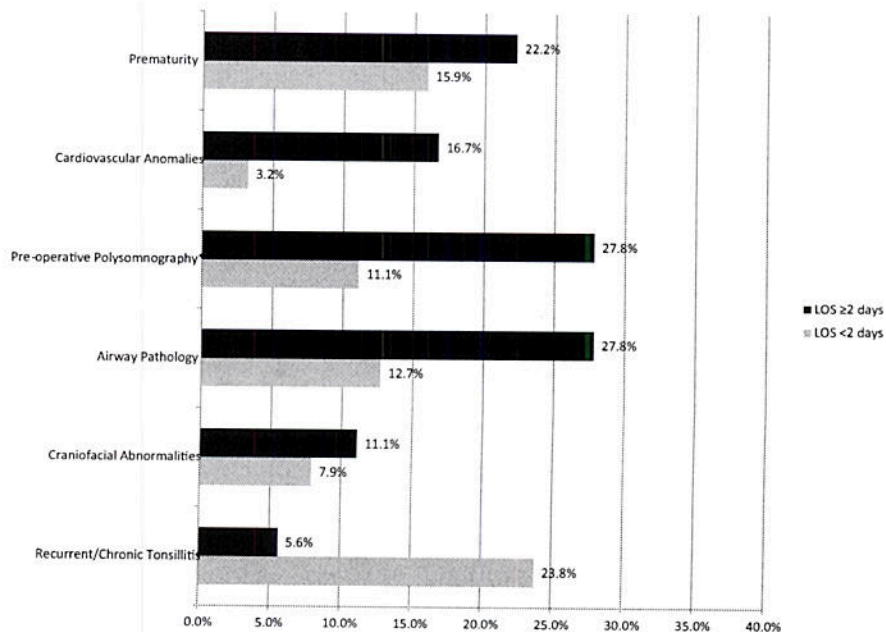


Fig. 2. Lengths of stay. Patients with GER who experienced longer hospitalizations had a higher percentage of prematurity, cardiovascular anomalies, and airway pathology. PSGs (*) showed more severe OSA (median AHI 22.9 vs. 8.2).

All children with GER who experienced complications during the first 24 h after surgery had other risk factors for postoperative complications. The limited size of the population precluded statistical analysis, but the eight (9.9%) children who experienced early complications were younger and had co-existing comorbidities, such as Beckwith–Wiedemann syndrome and cardiac defects.

Six of the complications experienced by the 8 children with GER were airway-related. The impact of gastroesophageal reflux on the upper airway of children and its potential contribution to airway compromise has been previously described [13,15,17,18]. A study out of Children's Memorial Hospital in Chicago, IL examined secondary airway lesions in young children undergoing adenotonsillectomy [18]. They described tracheal cobblestoning in 31.8% of their patients; this finding has been associated with GER and is often treated with anti-reflux therapy [19]. A similar study described synchronous airway lesions in children 18 months and younger undergoing adenoidectomy [17]. They found an overall prevalence of synchronous airway and/or esophageal findings of 77% and histologic evidence of GER in 31% of their patients.

Several studies have also characterized the impact of reflux on obstructive sleep apnea [20–22]. One study identified GER as a risk factor for adenoid regrowth and revision adenoidectomy [20]. It has also been proposed that children with OSA be screened for GER after proton-pump inhibitor therapy was demonstrated to improve AHI scores in children with both OSA and GER [22]. It should be noted that the greatest benefit in this study was seen in school-age children with mild OSA. Younger children with more severe OSA did not experience the same improvement.

Limitations of the current study include the small sample size and its retrospective nature. Statistical comparison of children with GER and children without GER was performed and included in the original larger study [11], but the smaller size of the current study precluded statistical analysis at this time. Not all included children had undergone objective testing for the diagnosis of GER at our institution. As is frequently the case with historical reviews, the inclusion diagnosis of GER, therefore, was made on documentation in the medical record. In addition, it is difficult to identify other coexisting but undiagnosed conditions that may also impact the upper aerodigestive tract, such as eosinophilic esophagitis. While the initial analysis included surgical technique and some intraoperative details such as blood loss, there is no way to fully control for unforeseen circumstances in each child's operation that may have impacted the immediate postoperative course.

5. Conclusion

There certainly exists a relationship between gastroesophageal reflux and upper aerodigestive tract inflammation and pathology in young children. The details of this relationship continue to be unraveled and future studies are certainly needed; however, randomized, controlled trials to investigate this phenomenon present a practical and ethical dilemma that make them difficult to carry out. Nonetheless, this review suggests that reflux appears to be a risk factor for postoperative problems in young children undergoing adenotonsillectomy. This provides further evidence for the potential value of evaluating for reflux in young children undergoing airway surgery. With this knowledge, the authors suggest that evaluations such as concurrent endoscopy may be

considered in young children undergoing adenoidectomy with or without tonsillectomy. Such practice may help identify synchronous airway findings or evidence of reflux that may change management and observation during the first 24 h after surgery. Lastly, more controlled studies are needed to help clarify these relationships in the future.

References

- [1] R.F. Baugh, S.M. Archer, R.B. Mitchell, R.M. Rosenfeld, R. Armin, J.J. Burns, et al., Clinical practice guideline: tonsillectomy in children, *Otolaryngol. Head Neck Surg.* 144 (January (1 Suppl.)) (2011) S1–S30.
- [2] K.A. Cullen, M.J. Hall, A. Golosinskiy, Ambulatory surgery in the United States, 2006, *Natl. Health Stat. Rep.* (January (11)) (2009) 1–25.
- [3] L.W. Pratt, R.A. Gallagher, Tonsillectomy and adenoidectomy: incidence and mortality, 1968–1972, *Otolaryngol. Head Neck Surg.* 87 (March–April (2)) (1979) 159–166.
- [4] M.J. Biavati, S.C. Manning, D.L. Phillips, Predictive factors for respiratory complications after tonsillectomy and adenoidectomy in children, *Arch. Otolaryngol. Head Neck Surg.* 123 (May (5)) (1997) 517–521.
- [5] M.E. Gerber, D.M. O'Connor, E. Adler, C.M. Myer 3rd., Selected risk factors in pediatric adenotonsillectomy, *Arch. Otolaryngol. Head Neck Surg.* 122 (August (8)) (1996) 811–814.
- [6] N.A. Goldstein, D.R. Arnfield, L.A. Kingsley, L.M. Borland, G.C. Allen, J.C. Post, Postoperative complications after tonsillectomy and adenoidectomy in children with Down syndrome, *Arch. Otolaryngol. Head Neck Surg.* 124 (February (2)) (1998) 171–176.
- [7] O.O. Nafiu, G.E. Green, S. Walton, M. Morris, S. Reddy, K.K. Tremper, Obesity and risk of peri-operative complications in children presenting for adenotonsillectomy, *Int. J. Pediatr. Otorhinolaryngol.* 73 (January (1)) (2009) 89–95.
- [8] K.H. Richmond, R.F. Wetmore, C.C. Baranak, Postoperative complications following tonsillectomy and adenoidectomy—who is at risk? *Int. J. Pediatr. Otorhinolaryngol.* 13 (August (2)) (1987) 117–124.
- [9] A.H. Werle, P.J. Nicklaus, D.J. Kirse, D.E. Bruegger, A retrospective study of tonsillectomy in the under 2-year-old child: indications, perioperative management, and complications, *Int. J. Pediatr. Otorhinolaryngol.* 67 (May (5)) (2003) 453–460.
- [10] B.J. Wiatrak, C.M. Myer 3rd, T.M. Andrews, Complications of adenotonsillectomy in children under 3 years of age, *Am. J. Otolaryngol.* 12 (May–June (3)) (1991) 170–172.
- [11] M.E. McCormick, A. Sheyn, M. Haupt, R. Thomas, A.J. Folbe, Predicting complications after adenotonsillectomy in children 3 years old and younger, *Int. J. Pediatr. Otorhinolaryngol.* 75 (November (11)) (2011) 1391–1394.
- [12] M.A. Gilger, Pediatric otolaryngologic manifestations of gastroesophageal reflux disease, *Curr. Gastroenterol. Rep.* 5 (June (3)) (2003) 247–252.
- [13] M.A. Kenna, The effect of gastroesophageal reflux on the pediatric airway, *Int. Anesthesiol. Clin.* 30 (4) (1992 Fall) 83–91.
- [14] J.G. May, P. Shah, L. Lemmonier, G. Bhatti, J. Kosciak, J.M. Cotichchia, Systematic review of endoscopic airway findings in children with gastroesophageal reflux disease, *Ann. Otol. Rhinol. Laryngol.* 120 (February (2)) (2011) 116–122.
- [15] R.F. Yellon, H. Goldberg, Update on gastroesophageal reflux disease in pediatric airway disorders, *Am. J. Med.* 111 (December (Suppl. 8A)) (2001) 78S–84S.
- [16] C.A. Hill, A. Litvak, C. Canapari, B. Cummings, C. Collins, D.G. Kearny, et al., A pilot study to identify pre- and peri-operative risk factors for airway complications following adenotonsillectomy for treatment of severe pediatric OSA, *Int. J. Pediatr. Otorhinolaryngol.* 75 (November (11)) (2011) 1385–1390.
- [17] D.L. Mandell, R.F. Yellon, Synchronous airway lesions and esophagitis in young patients undergoing adenoidectomy, *Arch. Otolaryngol. Head Neck Surg.* 133 (April (4)) (2007) 375–378.
- [18] J.C. Rastatter, J.W. Schroeder Jr., A. French, L. Holinger, Synchronous airway lesions in children younger than age 3 years undergoing adenotonsillectomy, *Otolaryngol. Head Neck Surg.* 145 (August (2)) (2011) 309–313.
- [19] M.M. Carr, A. Nguyen, C. Poje, M. Pizzuto, M. Nagy, L. Brodsky, Correlation of findings on direct laryngoscopy and bronchoscopy with presence of extraesophageal reflux disease, *Laryngoscope* 110 (September (9)) (2000) 1560–1562.
- [20] A.C. Dearking, B.D. Lahr, A. Kuchena, L.J. Orvidas, Factors associated with revision adenoidectomy, *Otolaryngol. Head Neck Surg.* 146 (June (6)) (2012) 984–990.
- [21] J. Wasilewska, M. Kaczmarek, K. Debkowska, Obstructive hypopnea and gastroesophageal reflux as factors associated with residual obstructive sleep apnea syndrome, *Int. J. Pediatr. Otorhinolaryngol.* (March) (2011).
- [22] J. Wasilewska, J. Semeniuk, B. Cudowska, M. Klukowski, K. Debkowska, M. Kaczmarek, Respiratory response to proton pump inhibitor treatment in children with obstructive sleep apnea syndrome and gastroesophageal reflux disease, *Sleep Med.* 13 (August (7)) (2012) 824–830.